

Case Report

Post auricular dermoid cyst: a rare occurrence

Abhijeet Dilip Kharche*, Sriranjani Iyer

Department Of General Surgery, RGMC, Kalwa, Thane, Maharashtra, India

Received: 16 February 2022

Accepted: 07 March 2022

***Correspondence:**

Dr. Abhijeet Dilip Kharche,

E-mail: abhijeetkharche1994@gmail.com

Copyright: © the author(s), publisher and licensee Medip Academy. This is an open-access article distributed under the terms of the Creative Commons Attribution Non-Commercial License, which permits unrestricted non-commercial use, distribution, and reproduction in any medium, provided the original work is properly cited.

ABSTRACT

Dermoid cysts are cystic, unilocular mobile soft tissue swelling, presenting with usually no symptoms; over midline of the body. Faciomaxillary dermoid cysts are a rare entity. They may be congenital or acquired. Congenital dermoid cysts are due to embryological defects in the fusion of six Hillocks of His. Acquired variety may be due to any penetrating injury. They must be differentiated from lipomas, hemangiomas, keloids and epidermoid cysts. We report a 15-year male child with cystic swelling on the left post auricular region which was found to be a dermoid cyst with no intracranial communication on ultrasound scan and facial computed tomography scan; with final confirmation on histopathological examination after surgical excision for cosmetic reasons.

Keywords: Dermoid cyst, Ear, Post-auricular

INTRODUCTION

Dermoid cysts on the facio-maxillary region are very rare, about 7% of all dermoid cysts.^{1,2} They are usually found in the midline of the body and at sites of embryonic fusions with components of keratin like hair, sebaceous glands etc.¹ This usually exists since birth but is usually recognised in the second or third decade of life when it grows in size.

Congenital dermoid cysts occur due to ectodermal entrapment in the branchial arch fusion while the acquired variety is due to a penetrating trauma causing the implantation of the epidermis into the dermis. Surgical excision must be complete so as to avoid recurrence as well as infection.³

Histopathological confirmation of the excised mass is necessary to rule out the possibility of malignancy. Although mostly benign, dermoid cysts have shown to have a component of endodermal sinus tumour in the paediatric population and squamous cell carcinoma in adults.

CASE REPORT

A 15-year-old male child came with a complaint of swelling in the left post auricular area. Swelling was present since birth but had gradually increased in size over the past 2 years till present size. The swelling was ovoid in shape, 5×2 cms, cystic, non-tender, mobile mass, non-compressible, with no local rise in temperature with no overlying skin changes. There was no history of trauma or bite. There were no associated hearing complaints, or any other birth anomalies. On an ultrasonography scan of the swelling an encapsulated homogeneous cystic swelling with clear fluid inside was found in the subcutaneous plane. On computed tomography scan, a subcutaneous cystic swelling of size 5×2 cms was found with no intracranial communication. Considering differential diagnosis of dermoid cyst, sebaceous cyst and lipoma and a provisional diagnosis of post-auricular dermoid cyst; patient was subjected to complete surgical excision of the swelling under local Anesthesia for cosmetic purpose. Intraoperatively, the cyst extended from the pinna at root of the helix till mastoid in posterior auriculocephalic sulcus. Post-

operative surgical site was found healthy on post-operative day 8. On histopathological examination it was found to be cystic swelling with tufts of hair inside and lined by stratified keratinized squamous epithelium suggestive of dermoid cyst. Patient was stable with no recurrence in the 6 months follow up period.

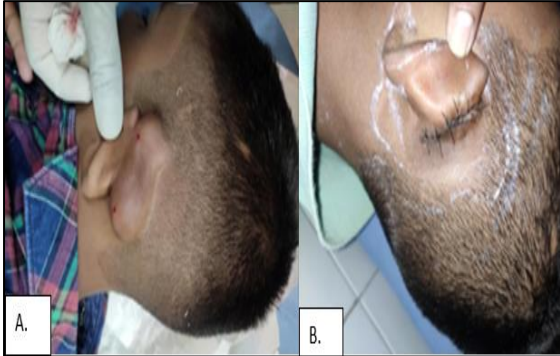

Figure 1: (A) Dermoid cyst over left posterior auriculocephalic sulcus, (B) Post-operative sutured site.

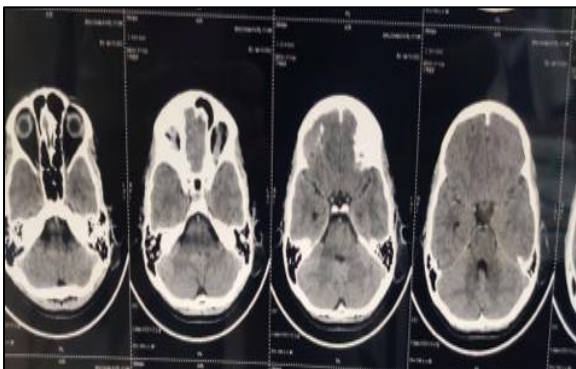


Figure 2: Computed Tomography scan of brain suggestive of subcutaneous cystic swelling with no intracranial communication.

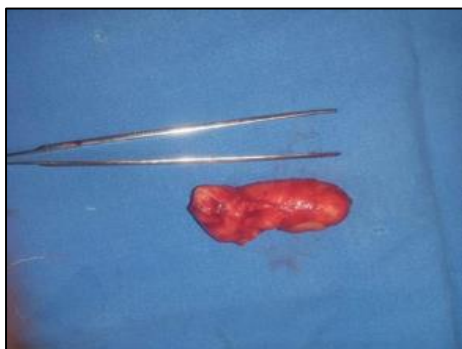


Figure 3: Post-operative image of excised left post auricular dermoid cyst.

DISCUSSION

Dermoid cysts are rare benign cysts found at sites of embryonic fusions.¹ Dermoid cysts are classified into

epidermoid, dermoid and teratoid cysts histologically.⁴ Dermoid cysts of the facio-maxillary region are formed due to entrapment of ectodermal components between first and second branchial arch during embryonic life.^{2,5} Ectodermal component could be hair follicle, sebaceous glands or any adnexal structure.^{3,6} They are rare and found in midline of body but post auricular is the rarest among them.³ Mostly they are asymptomatic and can be congenital or acquired.^{1,2,7} Acquired dermoid cysts are formed due to penetrating injuries.⁸ Patients present to hospitals for cosmetic reasons. Dermoid cysts grow slow and gradually.⁹

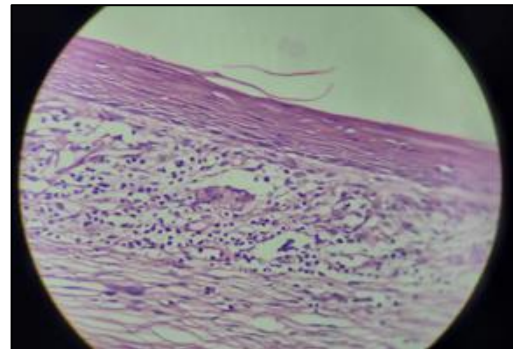


Figure 4: Histopathological image showing encapsulated cyst lined by stratified keratinized squamous epithelium suggestive of dermoid cyst.

Initial clinical assessment itself rules out most differentials like lipoma, sebaceous cyst but use of different radiological methods can help to narrow down to the diagnosis. Ultrasound scan can be one of initial modalities for diagnosis and computed tomography scan for radiological confirmation and to exclude intracranial communication.

Surgical excision is indicated for cosmetic purpose and complete excision lowers the chances of recurrence.³ Incomplete excision can also lead to postoperative infection.³

Histopathological examination shows stratified keratinized squamous epithelium with hair follicles and confirms diagnosis of dermoid cyst with no malignant transformation. It has a good prognosis.²

CONCLUSION

Dermoid cysts are rare in craniofacial regions and post auricular cysts are rare among them. Mostly they are asymptomatic and surgery is indicated for cosmetic purpose. Diagnosis is easier with computed tomography scan and histopathological confirmation is must to rule out any other malignant pathology. Complete excision must be done to avoid recurrence.

Funding: No funding sources

Conflict of interest: None declared

Ethical approval: Not required

REFERENCES

1. Kim SH. Pedunculated tragal dermoid cyst misdiagnosed as an accessory tragus. *Br J Oral Maxillofac Surg.* 2016;12:1-4.
2. Cho Y, Lee DH. Clinical characteristics of idiopathic epidermoid and dermoid cysts of the ear. *J Audiol Otol.* 2017;21:77-80.
3. Pryor SG, Lewis JE, Weaver AL. Pediatric dermoid cysts of the head and neck. *Otolaryngol Head Neck Surg.* 2005;132:938-42.
4. Jung KH, Choi HJ, Nam DH. Characteristics of Dermoid Cyst of the Auricle. *Arch CraniofacSurg.* 2014;15(1):22-7.
5. Jacquin A, Bejot Y, Hervieu M. Rupture of intracranial dermoid cyst with disseminated lipid droplets. *Rev Neurol (Paris).* 2010;166:451-7.
6. Fitzpatrick TB, Johnson RA, Wolff K. *Fitzpatrick's Color Atlas and Synopsis of Clinical Dermatology.* 5th ed New York: McGraw-Hill. 2005.
7. Horikiri M, Ueda K, Kato M. Dermoid cyst of the auricle: a rare manifestation. *BMJ Case Rep.* 2014;2014:bcr2014205826.
8. Moon IH, Lee WH, Joo JB, Cho JE. A case of postauricular dermoid cyst. *Korean J Otolaryngol-Head Neck Surg.* 2005;48:1294-6.
9. Kandogan T, Koç M, Vardar E, Selek E, Sezgin O. Sublingual epidermoid cyst: a case report. *J Med Case Rep.* 2007;1:87.

Cite this article as: Kharche AD, Iyer S. Post auricular dermoid cyst: a rare occurrence. *Int Surg J* 2022;9:917-9.